

Treatment of Neuropathic Pain in a Patient With Diabetic Neuropathy Using Transcutaneous Electrical Nerve Stimulation Applied to the Skin of the Lumbar Region

Background and Purpose. Diabetic neuropathy can produce severe pain. The purpose of this case report is to describe the alteration of pain in a patient with severe, painful diabetic neuropathy following application of transcutaneous electrical nerve stimulation (TENS) to the low back. **Case Description.** The patient was a 73-year-old woman with pain in the left lower extremity over the lateral aspect of the hip and the entire leg below the knee. The pain prevented sound sleep. The intensity of pain was assessed with a visual analog scale. **Intervention.** The TENS (80 Hz) was delivered 1 to 2 hours a day and during the entire night through electrodes placed on the lumbar area of the back. **Outcomes.** Following 20 minutes of TENS on the first day of treatment, the patient reported a 38% reduction in intensity of pain. After 17 days, the patient reported no pain following 20 minutes of TENS and that she could sleep through the night. Application of TENS to the skin of the lumbar area may be an effective treatment for the pain of diabetic neuropathy. [Somers DL, Somers MF. Treatment of neuropathic pain in a patient with diabetic neuropathy using transcutaneous electrical nerve stimulation applied to the skin of the lumbar region. *Phys Ther.* 1999;79:767-775.]

Key Words: *Diabetes, Pain, Peripheral neuropathy, Transcutaneous electrical nerve stimulation.*

David L Somers

Martha F Somers

Diabetes mellitus is caused by an insufficient insulin-mediated response to blood glucose. People with the disorder are classified as being insulin dependent (ie, having type I diabetes) or non-insulin dependent (ie, having type II diabetes) depending on whether they require exogenous insulin for survival. A frequent sequella of both types of diabetes is the development of peripheral neuropathy in either motor or sensory nerves, or both.¹ Crawford² estimated that 13 million people in the United States have diabetes, and 30% to 40% of these people are believed to have at least sensory neuropathy.³

A consequence of any neuropathy affecting motor and sensory peripheral nerves is reduction or loss of strength and sensation. Another potential consequence of peripheral neuropathy in people with diabetes is severe, unremitting pain.^{1,4} People with painful diabetic neuropathy describe their pain as constant, burning, or searing. Allodynia, to light touch, the experience of light touch as painful, frequently develops, and even contact with bedclothes can be painful. Deep pain, described as being located in the center or marrow of the bone, can also occur. When pain is severe, people with diabetic neuropathy may have difficulty sleeping and can experience depression and weight loss.¹

The mechanism by which painful peripheral neuropathy occurs in people with diabetes is not well-understood; however, abnormal activation of damaged or regenerating peripheral nerves may be involved. These nerves become injured when intraneuronal levels of glucose become sufficiently high to saturate the normal metabolic pathway for the carbohydrate^{4,5} or when blood supply to the nerve becomes perturbed because of perineural vascular changes.⁴ Although all nerve fibers may be injured by these processes, small myelinated and unmyelinated fibers that conduct pain and temperature information are most affected.⁶⁻⁸ Once damaged, the axons of these small-diameter nerve fibers undergo regeneration,^{6,7} and pain may occur through abnormal activation of damaged or regenerating small-diameter nociceptive fibers.^{7,9} Thus, the perception of this pain is dependent on neurotransmission in the dorsal horn of the spinal cord.

***There is a growing
body of literature
indicating that high-
frequency TENS is
an effective pain-
relieving modality
for diabetic and
other painful
neuropathies.***

Given this etiology for the pain of diabetic neuropathy, a viable treatment would block the abnormal activity in the affected peripheral nerve or block neurotransmission in the somatotopically related dorsal horn. Transcutaneous or direct stimulation of sensory peripheral nerves is believed to produce anal-

gesia through both of these mechanisms. When the sciatic nerve is sectioned in the upper leg of rats, for example, and a neuroma is induced in the distal stump of the cut nerve, spontaneous activity develops in the neuroma.¹⁰ This spontaneous activity is believed to cause pain because it occurs in small-diameter, lightly myelinated peripheral nerve fibers, and many of these fibers are known to transmit painful information.¹¹ Even a 6-second direct stimulation (100 Hz) of the sciatic nerve proximal to the neuroma depresses abnormal, spontaneous activity from the neuroma for as much as an hour after the stimulation.¹⁰ Peripheral electrical stimulation can also block transmission of nociceptive impulses in the dorsal horn of the spinal cord. Five minutes of transcutaneous electrical nerve stimulation (TENS) (85 Hz) applied to the hind limb of primates reduces the responsiveness of nociceptive, spinothalamic projection neurons to noxious electrical stimulation of the same limb.¹² Moreover, evoked activity of dorsal horn neurons during painful mechanical stimulation in cats was reduced during TENS application (50–125 Hz) to the somatic receptive field of the same neuron.¹³

Because high-frequency TENS can suppress abnormal, spontaneous activity in a damaged peripheral nerve and can block nociceptive transmission in the dorsal horn, the use of this modality seems a viable treatment for the pain of diabetic neuropathy. Indeed, TENS applied to the lower extremities of patients with diabetic neuropathy reduced the intensity of pain experienced in the

DL Somers, PhD, PT, is Associate Professor, Department of Physical Therapy, John G Rangos, Sr, School of Health Sciences, Duquesne University, 105 Health Sciences Bldg, Pittsburgh, PA 15282 (somers@duq.edu). Address all correspondence to Dr Somers.

MF Somers, PT, is Instructor, Department of Physical Therapy, John G Rangos, Sr, School of Health Sciences, Duquesne University.

DL Somers and MF Somers provided the concept and research design, wrote the manuscript, and analyzed the data. MF Somers collected the data. F Richard Clemente, FCR, provided consultation (including review of the manuscript before submission).

This article was submitted May 29, 1998, and was accepted April 3, 1999.

© 1999 by the American Physical Therapy Association.

distal portion of the same limb.^{14,15} It is not known whether TENS would be as effective if it were delivered through electrodes placed on the skin of the low back, an alternative placement for treatment of pain in the lower extremities.^{16,17} This electrode placement delivers therapeutic stimulation through nonpathological nerves (dorsal rami) to many of the same spinal cord segments that innervate the lower extremity.¹⁸

For several reasons, such an alternative electrode placement might be desirable when TENS is used to treat people with painful diabetic neuropathy. First, large-diameter myelinated nerve fibers may be damaged in the painful extremities of people with severe diabetic neuropathy.^{4,8} Because activation of large-diameter myelinated nerve fibers is believed to be the mechanism by which high-frequency TENS produces analgesia,¹⁹ the modality may be more effective for people with severe neuropathy if it is delivered through undamaged peripheral nerves.

Another reason to consider not placing the electrodes on the painful extremity is the concern for integument integrity. Because vascular insufficiency so often affects the extremities of people with diabetes,^{20,21} skin breakdown is a common occurrence and an important concern. Although there is no evidence that TENS causes skin breakdown, the most prevalent side effect of TENS when used for pain relief is skin irritation.^{16,22} Consequently, it may be desirable to avoid placing the TENS electrodes on an involved extremity of a person with diabetes. Such a strategy also may be prudent when diabetic neuropathy results in diminished pain and temperature sensation, a frequent occurrence in the affected limb of people with diabetic neuropathy.¹ Even though high-frequency TENS is delivered at an intensity that is not painful, if therapeutic effectiveness can be achieved by placing electrodes over skin that can perceive pain, such placement would be the safest approach. The purpose of this case report is to describe the use of high-frequency TENS, delivered through electrodes placed on the low back, in the treatment of a patient with painful diabetic neuropathy.

Case Description

Patient Description

The patient was a 73-year-old woman who was admitted to the hospital with atrial fibrillation. Although the fibrillation was converted to a normal sinus rhythm with medication, the patient's stay at the hospital was extended after she fell from bed and fractured her right lateral malleolus 5 days after admission. The patient's right leg was casted below the knee, and she was transferred to a rehabilitation hospital 4 days after the fall.

She was referred to a physical therapist for gait training and therapeutic exercise.

The patient had a history of ventricular arrhythmias for which she was taking Procan* prior to admission. She was also taking medications for hypertension (Lopresor[†]) and angina pectoris (Isordil[‡]). The patient had a right cerebrovascular accident several years prior to admission and was taking prophylactic Ticlid[§] to prevent a second infarct. The patient had type I diabetes and self-administered Humulin N insulin.^{||} Three years prior to referral, she was diagnosed with painful diabetic neuropathy in the left lower extremity. She applied Zostrix[#] cream at home to control the pain, but she described this treatment as ineffective. The patient had sensory loss in a stocking distribution below both knees and wore bilateral ankle-foot orthoses to compensate for weakening dorsiflexors.

Examination

Cognitive function. The patient was alert and appeared to be highly motivated. She was able to respond to complex questions and commands, had a good recollection of her home environment, and had no difficulty communicating.

Range of motion and strength. In the joints that could be tested, the patient had no limitations in range of motion. Upper extremity strength was normal when evaluated by manual muscle testing,²³ with isolated joint motion present throughout. The muscles in the right lower extremity were 4/5 throughout, except those about the ankle. The cast prevented testing of the muscles that move the ankle, but the patient reported that she had experienced weakness in those muscles prior to the fracture. The muscles in the left lower extremity were 3/5 (Fair) to 2/5 (Poor) throughout, except the ankle dorsiflexors were 0/5 (Absent).

Sensation. Light touch sensation was examined using a cotton ball. The patient was asked to close her eyes and describe where on her skin she was being touched with the cotton ball. If she failed to perceive contact of the cotton ball with her skin, light touch was recorded as absent. When the patient could perceive contact of the cotton ball with her skin and correctly localize the stimulation, she was asked to compare the quality of the sensation with that

* Parke-Davis, Div of Warner-Lambert Co, 201 Tabor Rd, Morris Plains, NJ 07950.

† Novartis Consumer Health Inc, 560 Morris Ave, Summit, NJ 07901.

‡ Wyeth-Ayerst Laboratories, Div of American Home Products Corp, PO Box 8299, Philadelphia, PA 19101.

§ Roche Pharmaceuticals, Roche Laboratories Inc, 340 Kingsland St, Nutley, NJ 07110.

|| Eli Lilly and Co, Lilly Corporate Center, Indianapolis, IN 46285.

GenDerm Corp, 600 Knightsbridge Pkwy, Lincolnshire, IL 60069.

produced by similar contact with the skin of her face. Prior to light touch evaluation, the patient reported that sensation in the skin of her face was normal. If the sensation produced by the cotton ball in the tested dermatome was judged by the patient to be of equal quality to the sensation produced in the face, light touch was recorded as normal. If the sensation produced by the cotton ball in the tested dermatome was judged to be of lesser quality to that of the face, light touch was recorded as diminished. Pain sensation was evaluated using a pin. On each examined area, the pin was pushed onto the skin with the same force as was required to produce a painful sensation on the skin of the patient's face. This force was similar to that required to generate a painful sensation on the skin of the examiner's forearm, and great care was taken to ensure the force was insufficient to puncture or damage the skin.

Light touch and pain sensation were normal throughout the upper extremities, except for diminished pain sensation in the patient's fingers bilaterally. Light touch and pain sensation were normal above both knees in the lower extremities. Light touch and pain sensation were diminished from the knee joint distally in the left lower extremity and in the skin that could be tested around the cast in the right lower extremity. This "stocking-and-glove" loss of sensation is typical of diabetic neuropathy.¹

Pain. The patient reported severe burning pain in the left lower extremity in a stocking-like distribution below the knee. She also complained of burning pain in the skin overlying the lateral aspect of the left hip and of a more focal aching pain in the anterior aspect of the right ankle joint. The patient described the ankle pain as beginning after the lateral malleolus fracture.

Treatment

Therapeutic exercise and functional training were administered to the patient 2 times per day, 6 days a week, for 24 days. It was our impression that these activities did not worsen or lessen the patient's pain. This impression was based on reports from the patient that her pain remained relatively constant during her first 6 days of rehabilitation when only therapeutic exercise and functional training occurred. The pain was unchanged from that reported during the initial evaluation. For this reason, a detailed description of these treatments has been omitted.

Two treatments were delivered to relieve pain. Six days after referral for physical therapy, the patient began oral medication of Vicodin** (an opioid analgesic), Xanax^{††} (a central nervous system benzodiazepine-class drug),

and Pamelor^{‡‡} (a tricyclic antidepressant) at dosages consistent with manufacturers' recommendations detailed in the *Physician's Desk Reference*.²⁴ All 3 classes of drugs are routinely used to treat patients with neuropathic pain.⁵ Because the physical therapy schedule varied, therapy (including TENS) was not provided at a consistent interval after drug administration.

The second treatment that the patient received was TENS, initiated 7 days after referral for physical therapy. The therapist administering the TENS told the patient that TENS would not cure her pain but that it might help reduce her pain, and that TENS helps some people but not others.

The physical therapist prepared the skin by gently cleaning it with an alcohol wipe. A self-adhesive surface electrode (5.08 cm [2 in] square; Empi SoftTouch^{§§}) was placed about 1.3 cm (½ in) lateral to the right posterior superior iliac spine on the back. A second electrode was placed in the same position on the left side of the back. We selected this electrode placement for several reasons. First, we had previously used this electrode placement to relieve lower-extremity pain. Second, the skin receiving stimulation is innervated by the dorsal rami of multiple lumbar and sacral spinal nerves,¹⁸ which may permit therapeutic stimulation to be delivered to the dorsal horn of multiple spinal cord segments. Third, we believe that placing the electrodes on the skin of the back would be safer than placing the electrodes on the skin of the extremity with loss of pain sensation. Finally, the electrode placement was selected for convenience, allowing the TENS unit, wires, and electrodes to be close together and easily managed.

The electrodes were attached to a single channel of an Empi Epix XL transcutaneous electrical nerve stimulator^{§§} set at a constant frequency of 80 Hz. The intensity of stimulation (duration and amplitude are altered together in this unit) was slowly increased until the patient could perceive the stimulation but was not made uncomfortable. This intensity did not produce visible muscle contraction. The first application of TENS was a 20-minute trial period. The length of the trial period was based on the treating therapist's experience that 20 minutes is usually sufficient to see a beneficial effect with TENS, a notion consistent with previous reports of TENS effectiveness.²⁵ The patient reported that she had less pain following TENS, and she was instructed in self-administration of the modality. At this time, she was also instructed to increase the intensity occasionally to overcome habituation.²⁶ After the trial and instructional

** Knoll Laboratories, Div of Knoll Pharmaceutical Co, 3000 Continental Dr N, Mount Olive, NJ 07828.

†† Pharmacia & Upjohn Co, 7000 Portage Rd, Kalamazoo, MI 49001.

‡‡ Sandoz Pharmaceuticals Corp, Dorsey Div, Sandoz Div, Rte 10, East Hanover, NJ 07936.

§§ Empi Inc, 599 Cardigan Rd, St Paul, MN 55126.

session, the patient used the TENS unit as she desired to relieve pain. She reported using it occasionally for 1 to 2 hours during the day and more often at night. The patient continued with this regimen until discharged from physical therapy (24 days).

Outcome measures. Three methods were used to assess the patient's perception of her pain. The first method was used once on initial evaluation. The patient was asked to express the magnitude of her pain on a scale of 0 to 10, with 0 being "no pain at all" and 10 being "the worst pain you can imagine." The second and third assessments were used multiple times. The second assessment was used to document the area of the body that was painful. The patient was given a sketch of the body (Figs. 1 and 2) and was asked to draw the areas of her body that were painful. Although the reliability of this method of assessment is not known, the patient's drawings were consistent with her description of the location and extent of the painful area. Finally, a visual analog scale (VAS) was used to assess the intensity of perceived pain. For each painful area identified, the patient was given a 10-cm line and asked to draw on the line the intensity of pain she was feeling. The left end of the line represented "no pain at all," and the right end of the line represented the "worst pain you can imagine." The patient's mark on the line was measured (in centimeters) with a ruler. The VAS is a reliable and valid tool for the quantification of perceived pain.²⁷⁻²⁹ In addition, the size of the scale and the end phrase used for the right end of the line are known to be more reliable than other sizes and end phrases.³⁰

Outcome

Figure 1 illustrates the area of painful skin and intensity of pain that the patient reported on the day of her initial physical therapy evaluation (Fig. 1A) and 6 days later when her oral pain medication commenced (Fig. 1B). The painful areas of skin in the left lower extremity were not altered by the oral pain medication; however, the patient no longer identified the anterior aspect of the right ankle joint as painful. Following the start of oral pain medication, the patient reported a reduction in pain in the right ankle from 4.0 cm to zero on the VAS, but only a slight diminution of pain in the lateral aspect of the left hip and the left leg below the knee.

Figure 2 illustrates the area of painful skin and the intensity of pain experienced by the patient with and without TENS at 2 subsequent evaluations. In an effort to be consistent with the original trial of TENS, pain always was assessed after the patient received TENS for 20 minutes. We did not ask the patient whether any relief she felt after 20 minutes was the maximal relief she experienced when using the modality. Seven days after referral for physical therapy, before use of TENS, the area of skin in which the patient reported pain in the left

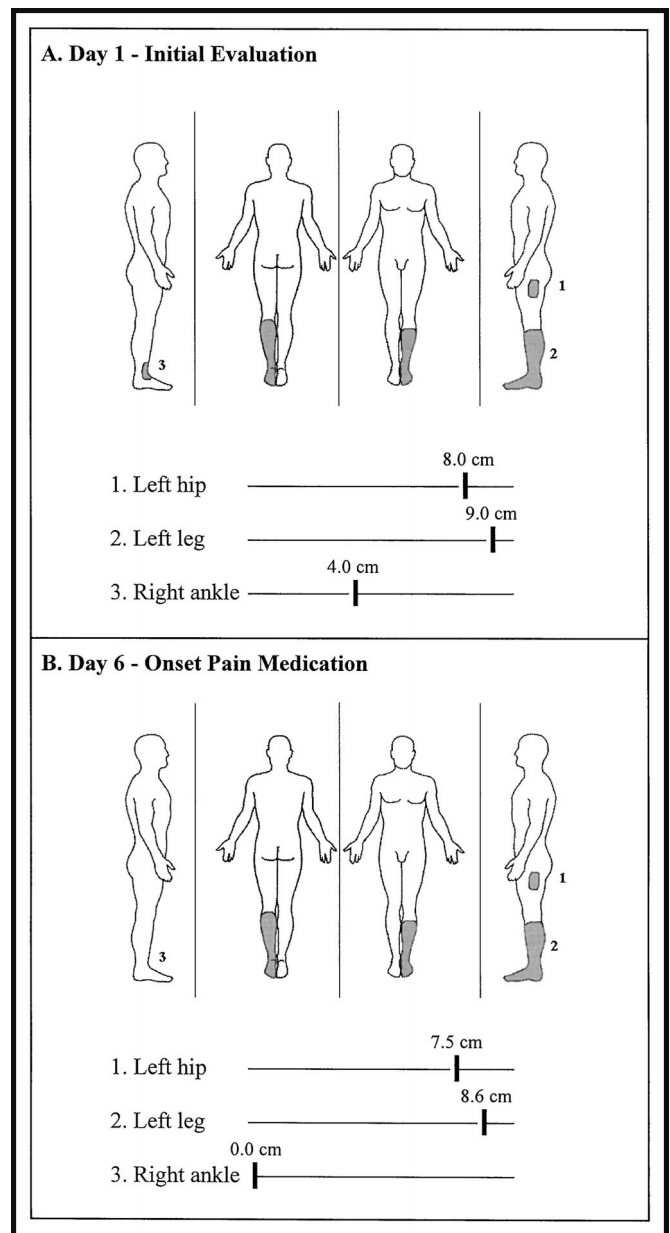


Figure 1.

Area and intensity of pain reported on the day of initial physical therapy evaluation (A) and 6 days later when oral pain medication commenced (B). The shaded areas on each sketch depict the area over which pain was experienced and are identical representations of the actual marks made by the patient on a similar sketch. The visual analog scales are depicted beneath each drawing and correspond to the numbered shaded areas. Note that the pain intensity shown in Fig. 1A is a visual analog scale depiction of the oral report taken from the patient.

lower extremity was not altered from that reported at the initial evaluation (Figs. 1A and 2A). After 20 minutes of TENS, the patient continued to experience pain over the same area (Fig. 2A); however, the intensity of pain was reduced from 7.4 to 4.6 cm (2.8 cm change) on the VAS.

For the next 17 days, the patient took oral medications for pain and wore the TENS unit during the night and

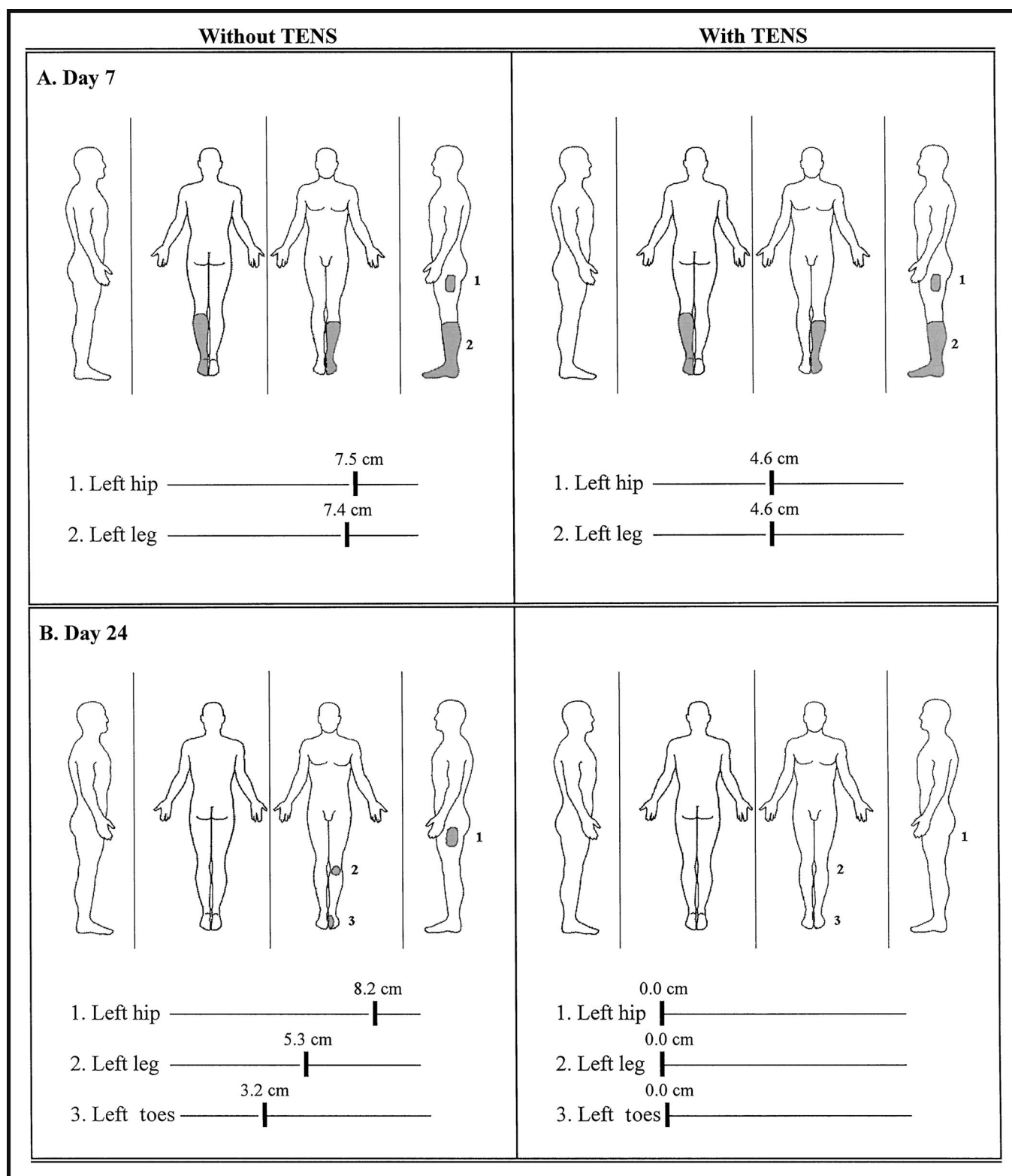


Figure 2.

Pain following transcutaneous electrical nerve stimulation (TENS) on day 7 (A) and day 24 (B) of physical therapy. The area and intensity of pain before the patient applied TENS on each day are shown in the left panels of Figs. 2A and 2B. The area and intensity of pain after 20 minutes of TENS on each day are shown in the right panels of Figs. 2A and 2B.

occasionally during the day. During this time, she reported that TENS treatment was accompanied by a sufficient reduction of pain intensity to allow her to sleep through the night for the first time in years. A final evaluation was made on day 24, and the results are shown in Figure 2B. Before TENS application, the area of skin identified by the patient as painful was markedly smaller than that reported during the previous evaluation at 7 days (compare drawings in left panels of Figs. 2A and 2B). Most notably, the stocking-like distribution of pain in the left lower extremity was reduced to 2 small areas of pain over the anterior aspect of the left knee and the mediodorsal aspect of the left foot (Fig. 2B, left panel). After 20 minutes of TENS, the intensity of pain in all 3 areas was reduced to zero on the VAS (Fig. 2B; right panel).

Discussion

This report describes a woman with severe diabetic neuropathy who was treated with TENS delivered to the skin of the low back. Seven and 24 days after her referral for physical therapy, the intensity of pain experienced by the patient after 20 minutes of TENS was reduced by 2.8 to 2.9 cm and by 8.5 to 3.2 cm, respectively, depending on the site of pain. Although it might be argued that this reduction was a placebo effect, this explanation seems unlikely for several reasons. First, the reduction of pain following TENS increased over time. On day 7, TENS administration was followed by a reduction, but not abolition, of pain in the left lower extremity at all painful sites. By day 24, pain reduction after TENS was complete with the patient marking zero on the VAS scale for all painful areas. At least in patients with back pain, placebo TENS does not produce a cumulative relief of pain, whereas actual TENS does produce such pain relief.³¹ Second, it seems likely that if the patient experienced a placebo-induced reduction of neuropathic pain following TENS, she would also experience a placebo-induced reduction of neuropathic pain following pain medication. This was not the case. At least at days 6 and 7, when the patient was taking only oral pain medications, there was no substantial reduction of pain intensity in the left lower extremity. Finally, the reduction in pain intensity reported here is typical of that observed in patients with diabetic neuropathy or back pain (≈ 2 cm)³¹ who were treated with actual TENS. When patients with diabetic neuropathy or back pain were treated with placebo TENS, the reduction in pain intensity was about 0.5 cm.^{14,31} This final point must be taken with caution because the reductions in pain previously reported are mean values and they are being compared with the pain reduction we report here for a single patient.

Because oral pain medications and TENS were both administered for 17 days, it is difficult to say with certainty how much each treatment contributed to

reducing the patient's pain. However, she described 2 types of pain from apparently different origins, and these pain types responded differently to pain medication and TENS. A dull aching pain was present in the right ankle, and burning pain was present in the left lower extremity. Although dull aching pain is a symptom that can occur with diabetic neuropathy,⁴ the patient had no history of this pain prior to her ankle fracture. This observation suggests that the patient's right ankle pain was caused by the lateral malleolus fracture rather than by diabetic neuropathy. The pain in the left lower extremity, however, was long-standing and diagnosed as being caused by diabetic neuropathy. Although the pain of the right ankle was completely eliminated by 2 days of pain medication, the burning pain in the left extremity was largely unchanged by this regimen. Twenty minutes of TENS on day 7, however, was followed by an immediate reduction in burning pain in the left lower extremity. This phenomenon was repeated at day 24, even after 17 days of pain medication. The response of neuropathic pain following TENS, but not following drug therapy, suggests that TENS was the more effective treatment for the acute relief of this patient's neuropathic pain. Although it is possible that TENS was only effective for this patient because she was also taking pain medications, such a contention is inconsistent with the TENS-induced pain relief reported for patients with diabetes who received TENS to their painful extremities.¹⁴ In that study,¹⁴ TENS relieved neuropathic pain even though all pain medications were discontinued for the study.

There are 2 potential mechanisms by which high-frequency TENS can relieve the pain of diabetic neuropathy. It is possible that TENS alleviates pain by directly blocking abnormal spontaneous activity in small-diameter, pain-mediating peripheral nerves.¹⁰ This mechanism requires electrical stimulation to be applied directly to the spontaneously active nerve. In addition, TENS can relieve the pain of diabetic neuropathy by altering nociceptive transmission in the dorsal horn of the spinal cord.^{12,13} The second mechanism requires that stimulation be delivered to spinal cord segments that innervate the painful area. The mechanism by which TENS may have reduced pain in our patient is unknown. Any TENS-induced relief experienced, however, could not be the result of directly blocking abnormal spontaneous activity in damaged peripheral nerves. The TENS was delivered through electrodes placed over the low back; thus, therapeutic stimulation was administered to the dorsal rami of spinal nerves.¹⁸ Because dorsal rami do not innervate the skin of the leg, their stimulation by TENS cannot directly block spontaneous activity in the peripheral nerves innervating the painful area. Many of the same spinal cord segments that innervate the leg via ventral rami of spinal nerves, however, also innervate the skin of the low back via

dorsal rami.¹⁸ Thus, it is possible that when TENS was delivered to the low back of our patient, it could have relieved pain by blocking nociceptive transmission in the dorsal horn of the spinal cord.

Whatever the mechanism of pain relief, this report supports a growing body of literature indicating that high-frequency TENS is an effective pain-relieving modality for diabetic and other painful neuropathies. This appears to be true even when multiple electrode placements are used. For example, TENS applied through electrodes placed on the distal aspect of the thigh and proximal aspect of the leg or through a stocking electrode covering the painful leg reduced the pain reported by patients with diabetic neuropathy in the distal portion of the same limbs.^{14,15} High-frequency electrical stimulation also produced pain relief in patients with painful diabetic neuropathy when delivered directly to the dorsal columns of the spinal cord.³² Likewise, TENS delivered to the skin of painful extremities^{33–35} or direct stimulation of the dorsal columns³⁶ reduced the pain of causalgia, a painful peripheral neuropathy that develops following peripheral nerve injury. It should be noted that the stimulation characteristics used in all of these studies were widely divergent, yet still effective. For our patient, we used Empi's biphasic waveform (80 Hz, variable pulse width [200–400 microseconds], 44–60 mA). In other studies in which high-frequency TENS was used to reduce the pain of neuropathy, several biphasic waves (2–70 Hz, exponentially decaying, 4-millisecond pulse width, 35 V¹⁴; 40 Hz, 80-millisecond pulse width³³) and monophasic waves (100 Hz, 50 μ A¹⁵) were used. Taken together with our experience, it appears that multiple electrode placements and multiple different stimulation characteristics may be effective in relieving the pain of neuropathy.

We describe the use of TENS to treat lower-extremity neuropathic pain in a woman with diabetes. The modality was delivered using electrodes positioned over the lumbar region of the back. Although more controlled investigations are necessary to conclude that such an approach will be consistently successful, we have recently shown under rigorous experimental conditions that the approach is successful when used to treat nondiabetic, painful, peripheral neuropathy in the hind paws of rats.³⁷ Taken together with the present report, these findings suggest that TENS delivered through the lumbar area of the back is a promising treatment for the relief of lower-extremity neuropathic pain.

References

- 1 Watkins PJ. Natural history of diabetic neuropathies. *QJ Med.* 1990; 77:1209–1218.
- 2 Crawford JM. The pancreas. In: Kumar V, Cotran RS, Robbins SL, eds. *Basic Pathology*. 6th ed. Philadelphia, Pa: WB Saunders Co; 1997:557–578.
- 3 Harris M, Eastman R, Cowie C. Symptoms of sensory neuropathy in adults with NIDDM in the US population. *Diabetes Care.* 1993;16: 1446–1452.
- 4 Horowitz SH. Diabetic neuropathy. *Clin Orthop.* 1993;296:78–85.
- 5 Schoemaker JH. Pharmacological treatment of diabetic peripheral neuropathy: challenges and possibilities. *Br J Clin Pract.* 1994;48:91–96.
- 6 Brown MJ, Martin JR, Asbury AK. Painful diabetic neuropathy: a morphometric study. *Arch Neurol.* 1976;33:164–171.
- 7 Portenoy RK. Painful polyneuropathy. *Neurol Clin.* 1989;7:265–288.
- 8 Said G, Goulon-Goeau C, Slama G, Tchobroutsky G. Severe early-onset polyneuropathy in insulin-dependent diabetes mellitus: a clinical and pathological study. *N Engl J Med.* 1992;326:1257–1263.
- 9 Asbury AK, Fields HL. Pain due to peripheral nerve damage: an hypothesis. *Neurology.* 1984;34:1587–1590.
- 10 Wall PD, Gutnick M. Properties of afferent nerve impulses originating from a neuroma. *Nature.* 1974;248:740–743.
- 11 Collins WF, Nulsen FE, Randt CT. Relation of peripheral nerve fiber size and sensation in man. *Arch Neurol.* 1960;3:381–385.
- 12 Lee KH, Chung JM, Willis WD Jr. Inhibition of primate spinothalamic tract cells by TENS. *J Neurosurg.* 1985;62:276–287.
- 13 Garrison DW, Foreman RD. Decreased activity of spontaneous and noxiously evoked dorsal horn cells during transcutaneous electrical nerve stimulation (TENS). *Pain.* 1994;58:309–315.
- 14 Kumar D, Marshall HJ. Diabetic peripheral neuropathy: amelioration of pain with transcutaneous electrostimulation. *Diabetes Care.* 1997;20:1702–1705.
- 15 Armstrong DG, Lavery LA, Fleischli JG, Gilham KA. Is electrical stimulation effective in reducing neuropathic pain in patients with diabetes? *J Foot Ankle Surg.* 1997;36:260–263.
- 16 Snyder-Mackler L. Electrical stimulation for pain modulation. In: Snyder-Mackler L, Robinson AJ, eds. *Clinical Electrophysiology: Electrotherapy and Electrophysiological Testing*. Baltimore, Md: Williams & Wilkins; 1995:279–310.
- 17 Starkey C. Electrical agents. In: Starkey C, ed. *Therapeutic Modalities*. Philadelphia, Pa: FA Davis Co; 1999:231–233.
- 18 Gray H. Neurology. In: Williams PL, Warwick R, Dyson M, Bannister LH, eds. *Gray's Anatomy*. London, England: Churchill Livingstone; 1989:1123–1127.
- 19 Wall PD, Sweet WH. Temporary abolition of pain in man. *Science.* 1967;155:108–109.
- 20 Jörneskog G, Brismar K, Fagrell B. Skin capillary circulation severely impaired in toes of patients with IDDM, with and without late diabetic complications. *Diabetologia.* 1995;38:474–480.
- 21 Uccioli L, Mancini L, Giordano A, et al. Lower limb arterio-venous shunts, autonomic neuropathy and diabetic foot. *Diabetes Res Clin Pract.* 1992;16:123–130.
- 22 Meyler WJ, de Jongste MJL, Rolf CAM. Clinical evaluation of pain treatment with electrostimulation: a study on TENS in patients with different pain syndromes. *Clin J Pain.* 1994;10:22–27.
- 23 Hislop HH, Montgomery J, eds. *Daniels and Worthingham's Muscle Testing: Techniques of Manual Examination*. 6th ed. Philadelphia, PA: WB Saunders Co; 1995:2–3.
- 24 *Physicians' Desk Reference*. 51st ed. Montvale, NJ: Medical Economics Co; 1997:401–2988.
- 25 Johnson MI, Ashton CH, Thompson JW. An in-depth study of long-term users of transcutaneous electrical nerve stimulation (TENS): implications for clinical uses of TENS. *Pain.* 1991;44:221–229.

- 26 Spielholz NI, Nolan MF. Conventional TENS and the phenomena of accommodation, adaption, habituation, and electrode polarization. *Journal of Clinical Electrophysiology*. 1995;7:16–19.
- 27 Ahles TA, Ruckdeschel JC, Blanchard EB. Cancer-related pain, II: assessment with visual analogue scales. *J Psychosom Res*. 1984;28:121–124.
- 28 Ferraz MB, Quaresma MR, Aquino LR, et al. Reliability of pain scales in the assessment of literate and illiterate patients with rheumatoid arthritis. *J Rheumatol*. 1990;17:1022–1024.
- 29 Price DD, Harkins SW. Psychophysical approaches to pain measurement and assessment. In: Turk DC, Melzack R, eds. *Handbook of Pain Assessment*. New York, NY: The Guilford Press; 1992:111–134.
- 30 Seymour RA, Simpson JM, Charlton JE, Phillips ME. An evaluation of length and end-phrase of visual analogue scales in dental pain. *Pain*. 1985;21:177–185.
- 31 Marchand S, Charest J, Li J, et al. Is TENS purely a placebo effect? A controlled study on chronic low back pain. *Pain*. 1993;54:99–106.
- 32 Tesfaye S, Watt J, Benbow SJ, et al. Electrical spinal-cord stimulation for painful diabetic peripheral neuropathy. *Lancet*. 1996;348:1698–1701.
- 33 Richlin DM, Carron H, Rowlingson JC, et al. Reflex sympathetic dystrophy: successful treatment by transcutaneous nerve stimulation. *J Pediatr*. 1978;93:84–86.
- 34 Johansson F, Almay BG, Von Knorring L, Terenius L. Predictors for the outcome of treatment with high frequency transcutaneous electrical nerve stimulation in patients with chronic pain. *Pain*. 1980;9:55–61.
- 35 Cauthen JC, Renner EJ. Transcutaneous and peripheral nerve stimulation for chronic pain states. *Surg Neurol*. 1975;4:102–104.
- 36 Long DM, Erickson DE. Stimulation of the posterior columns of the spinal cord for relief of intractable pain. *Surg Neurol*. 1975;4:134–141.
- 37 Somers DL, Clemente FR. High-frequency transcutaneous electrical nerve stimulation alters thermal but not mechanical allodynia following chronic constriction injury of the rat sciatic nerve. *Arch Phys Med Rehabil*. 1998;79:1370–1376.